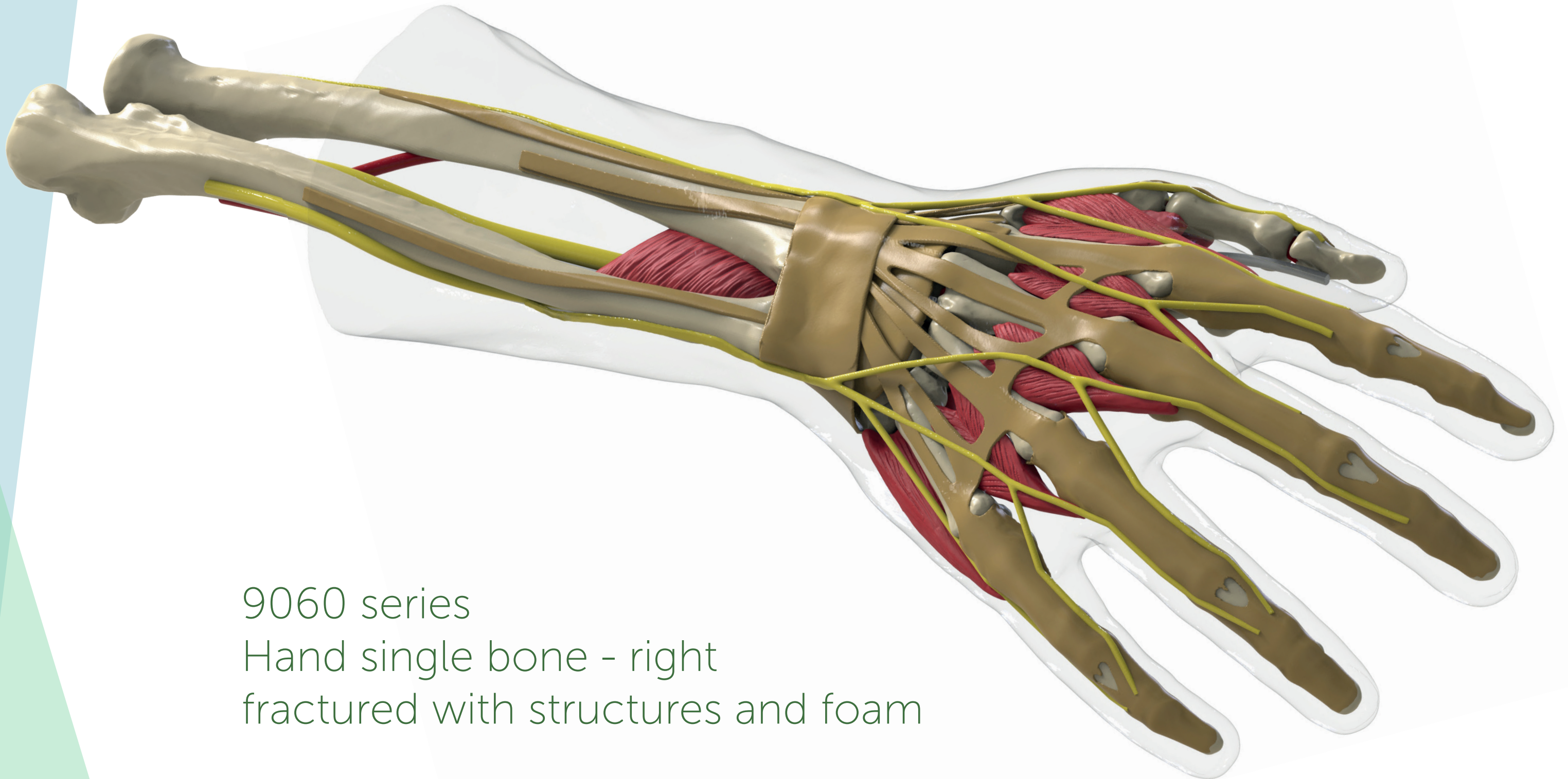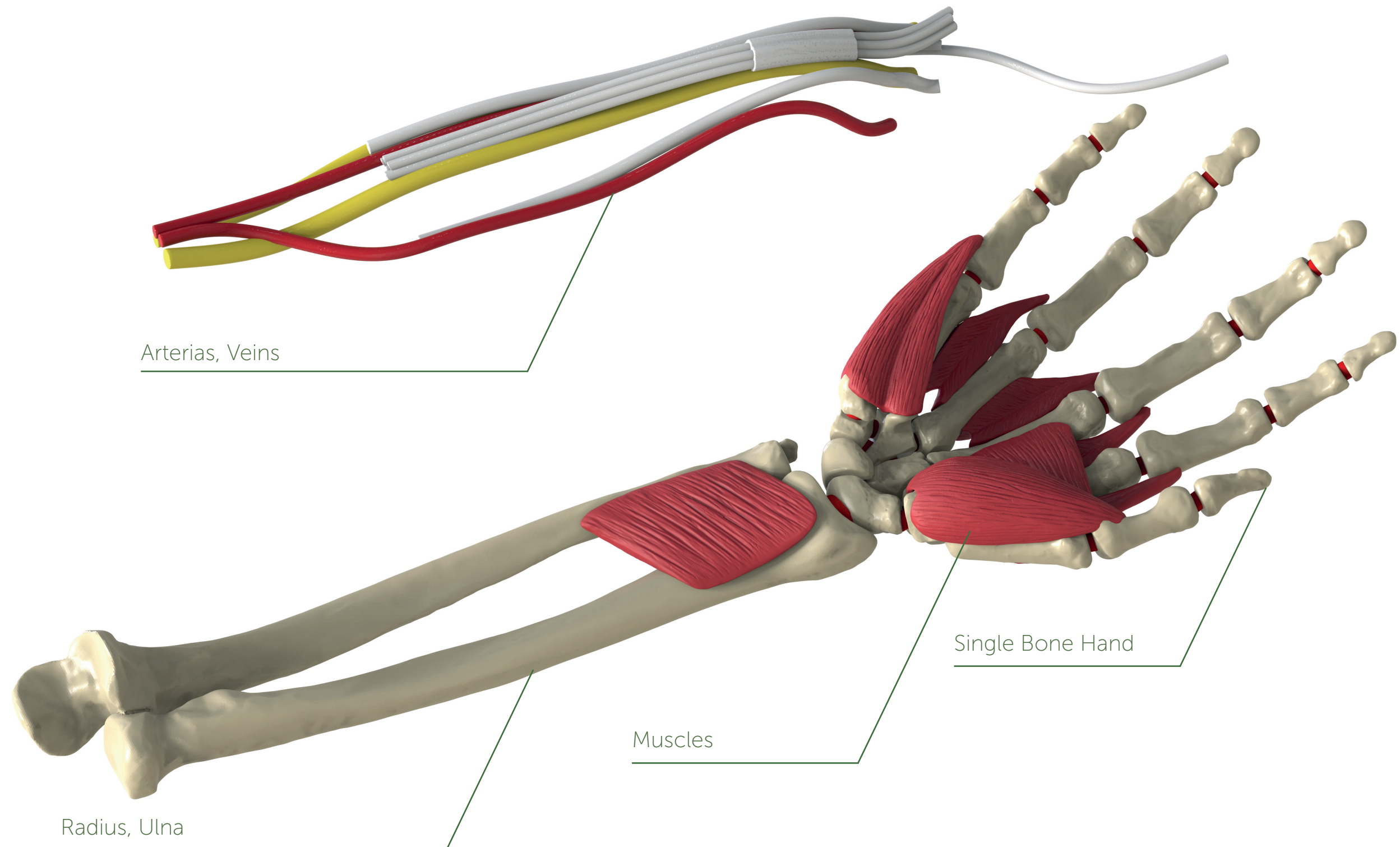


9060 series
Hand single bone - right
fractured with structures and foam



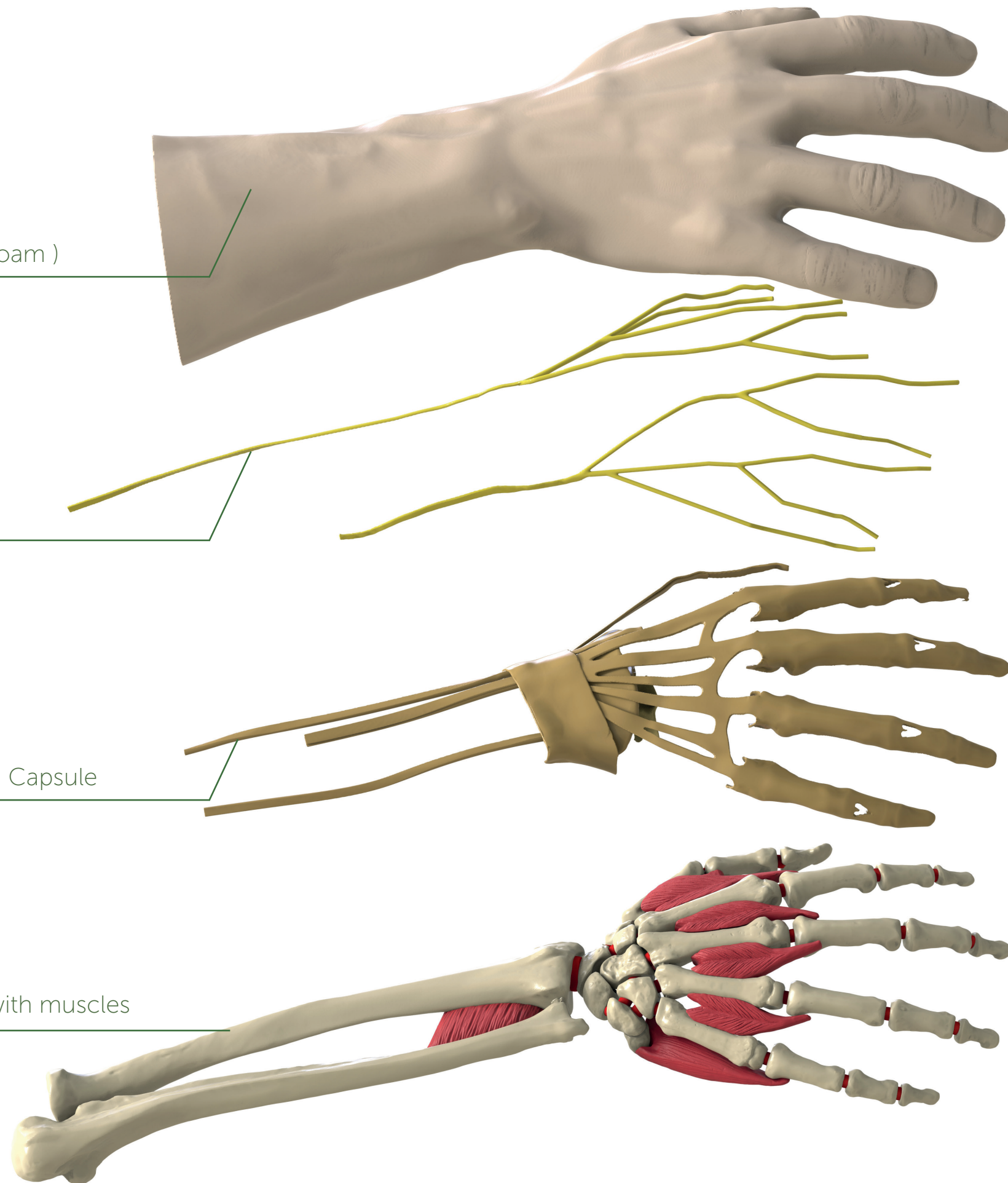
Dorsal view

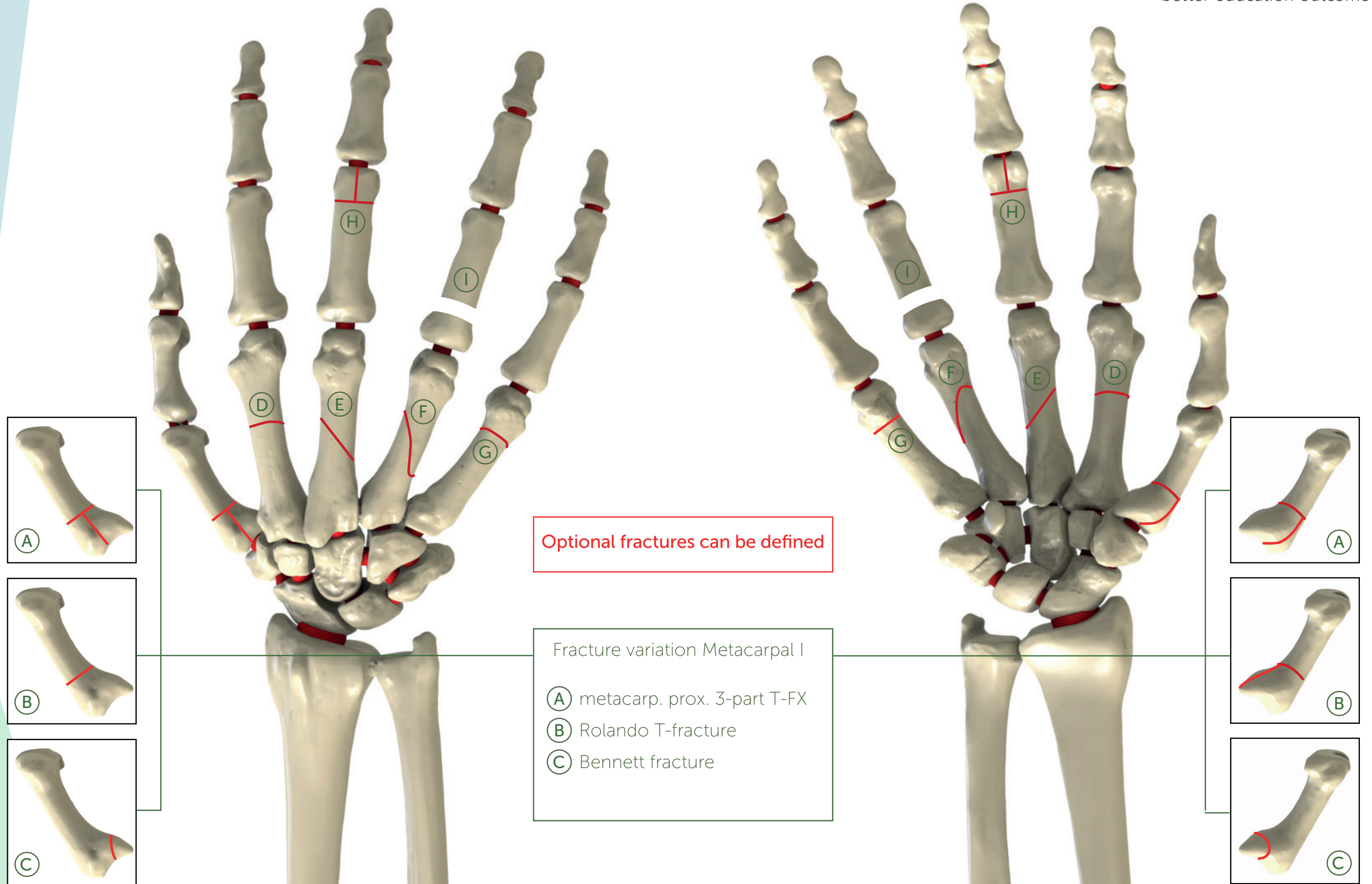
Hand soft tissue (Foam)

Nerves

Tendons, Ligament, Capsule

Single bone hand with muscles

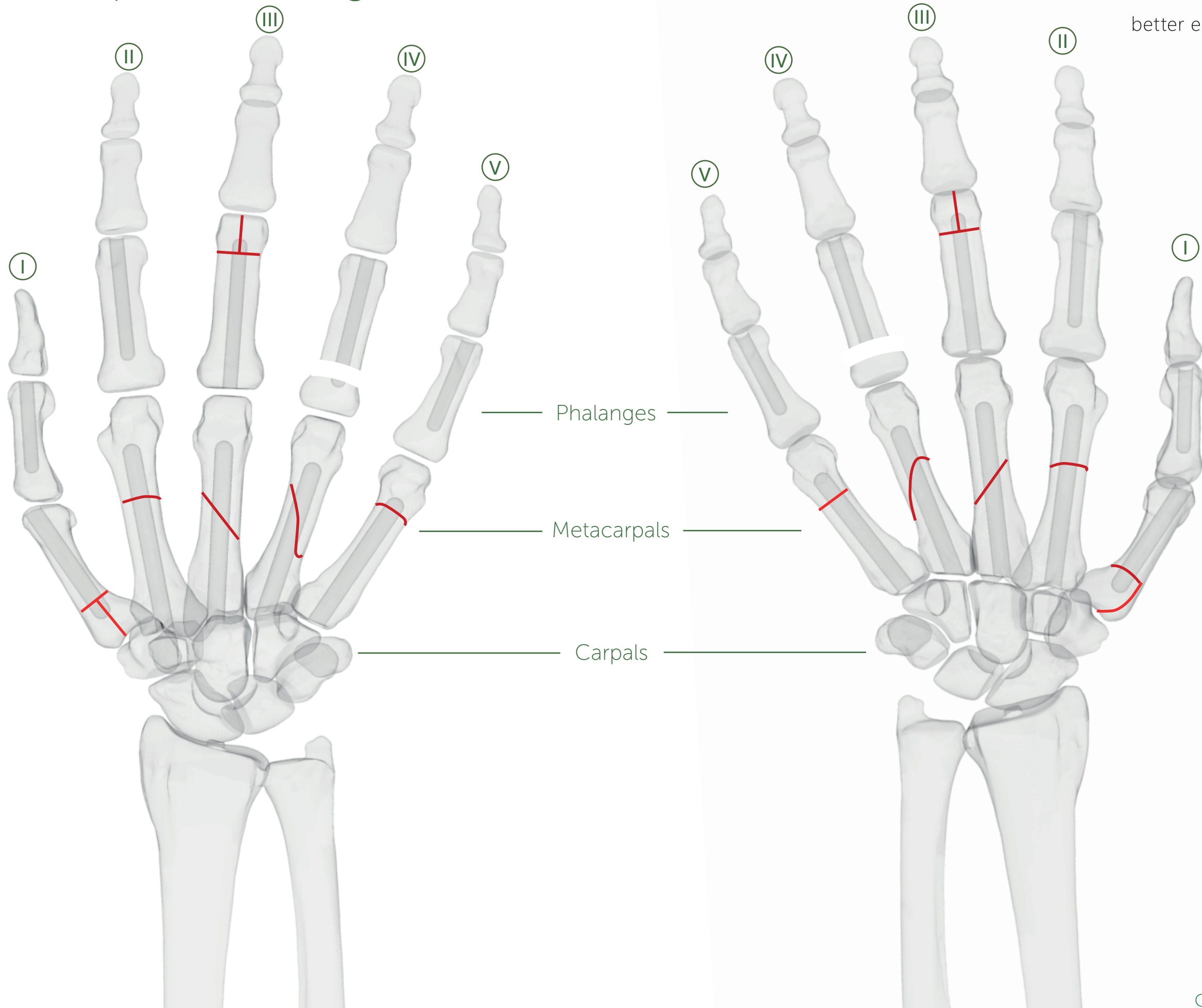


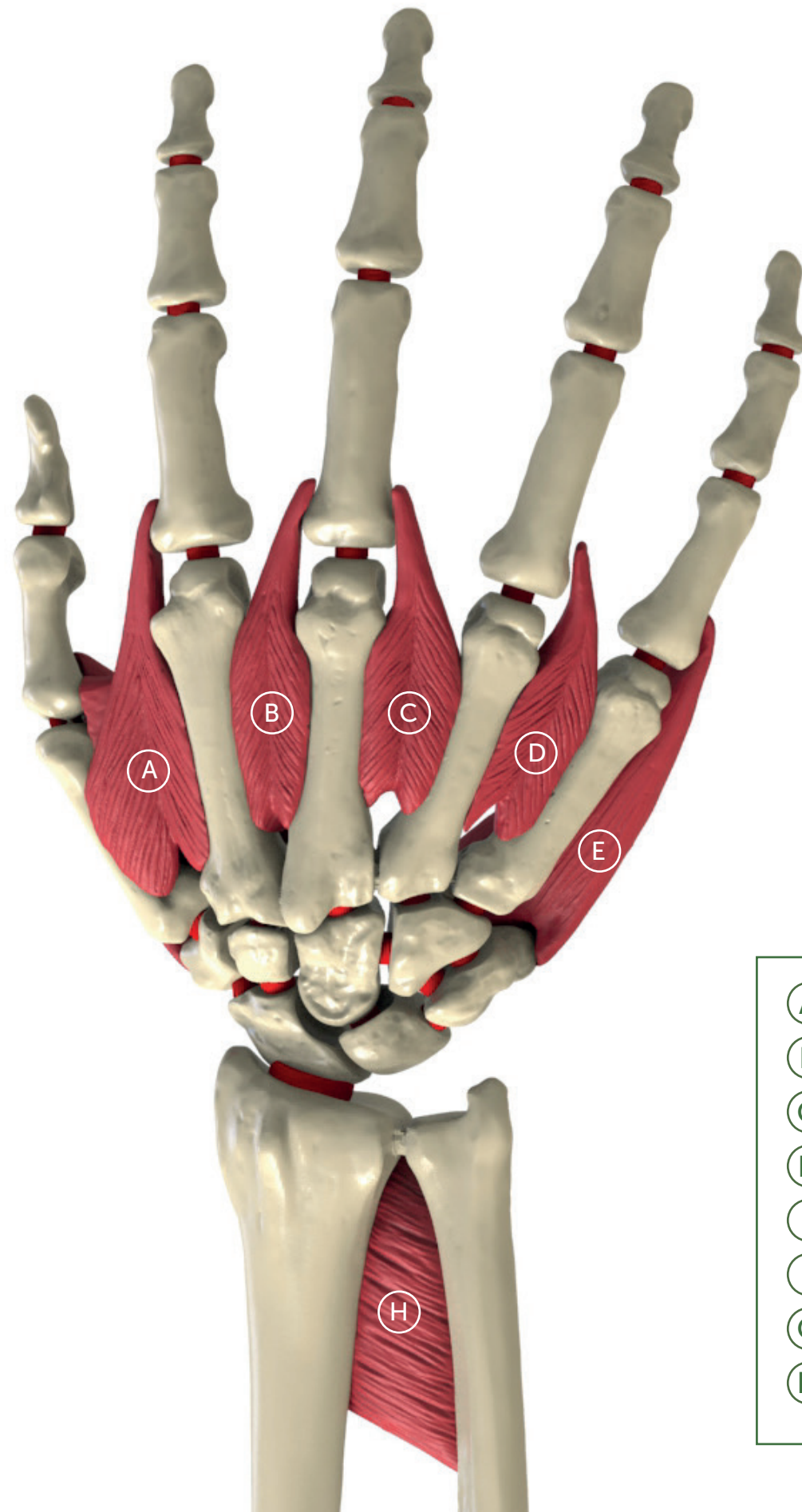


Metacarpal / Phalangeal canals

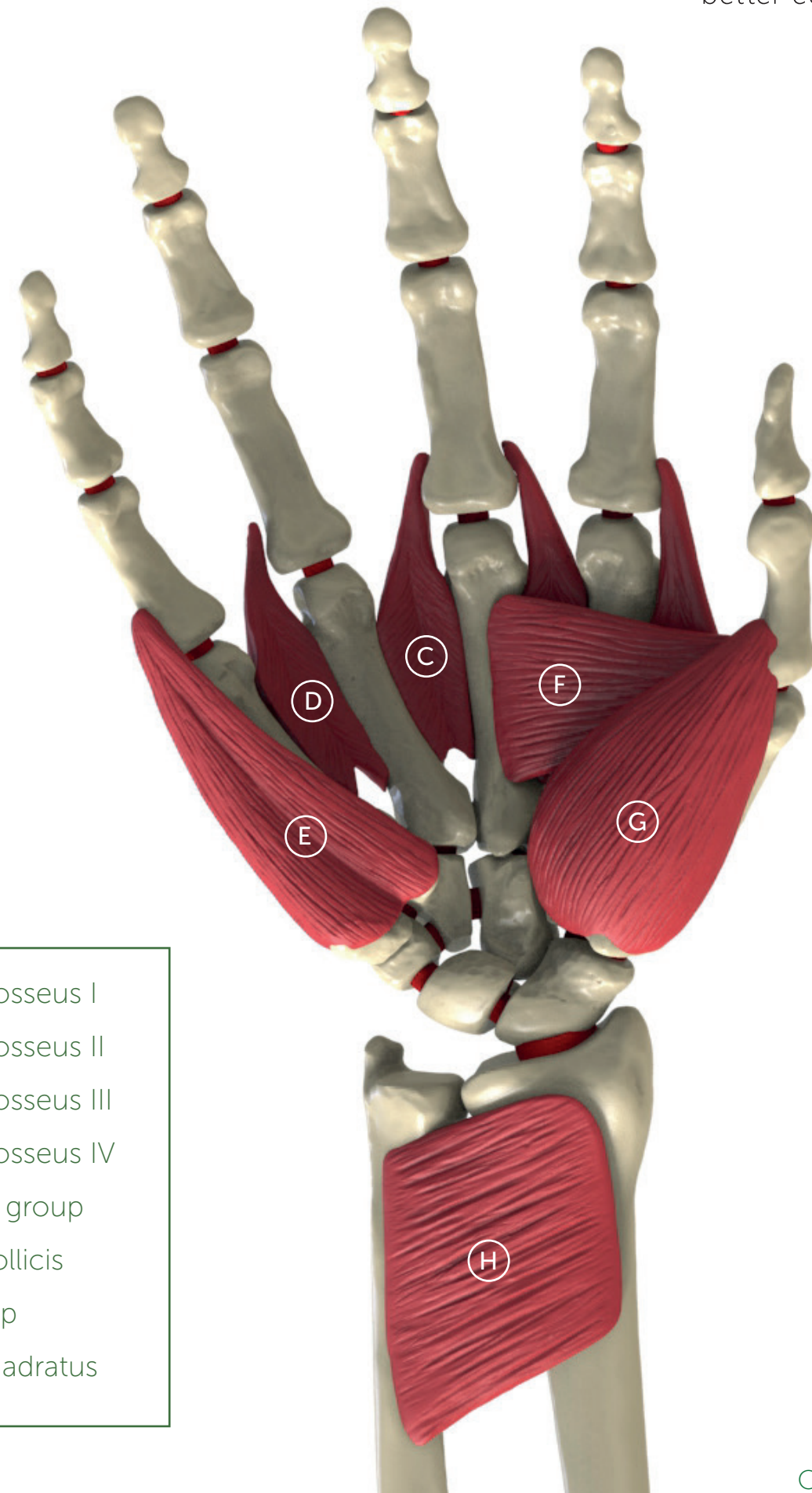
SYNBONE®

better education outcome

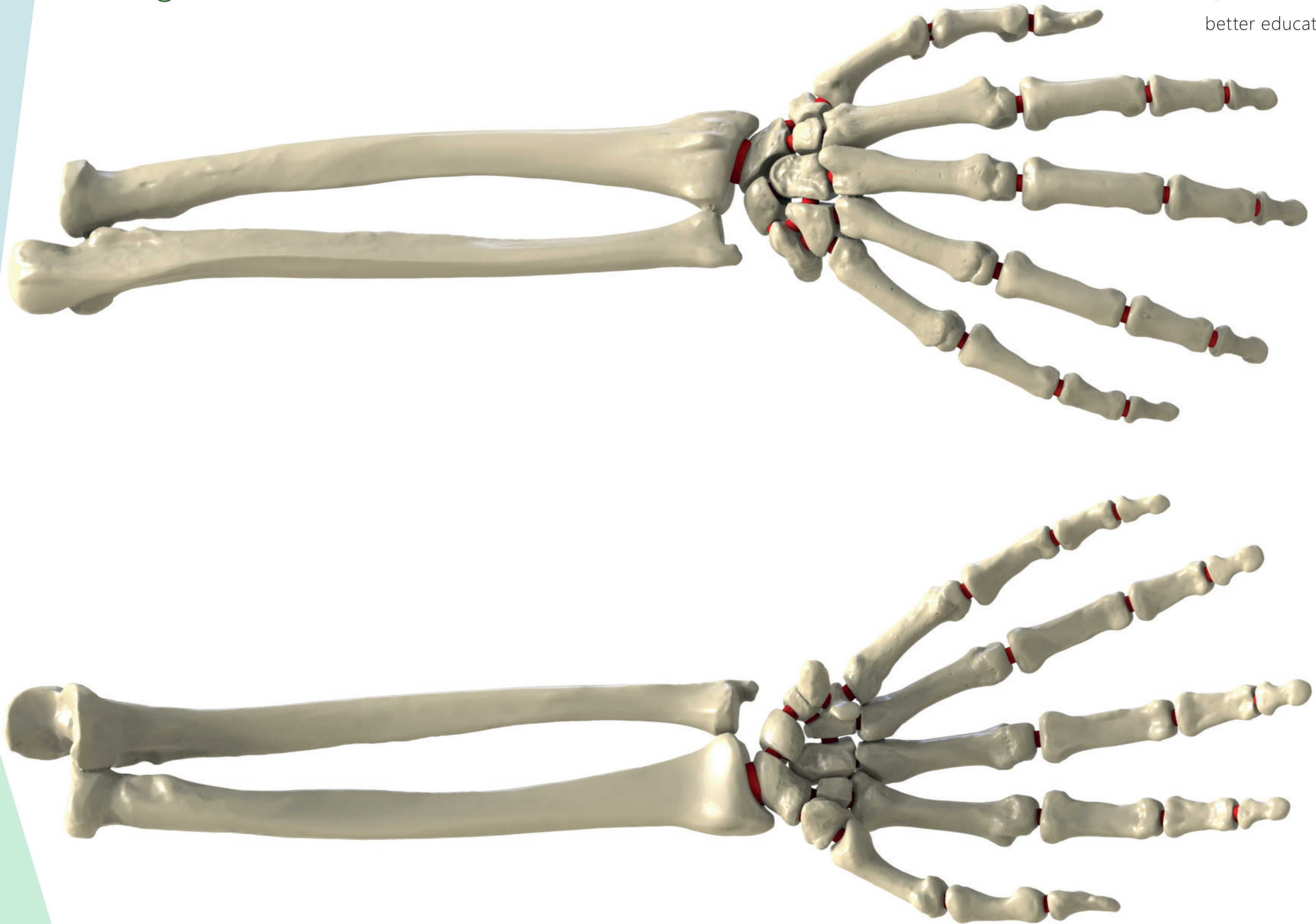


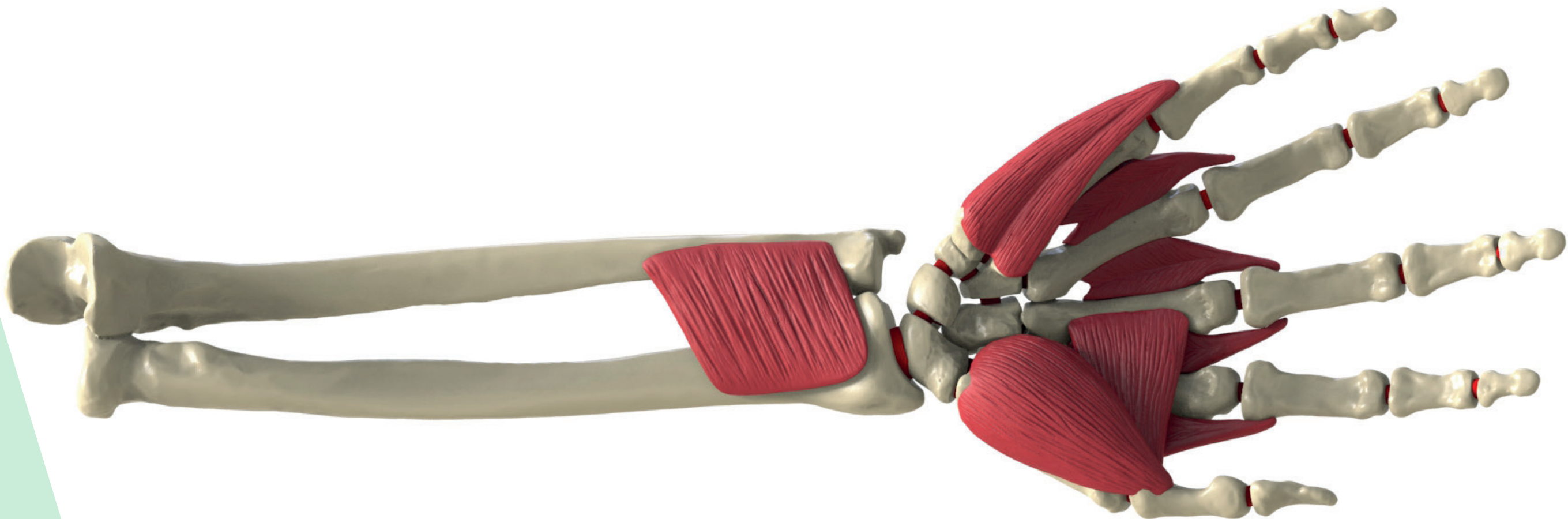
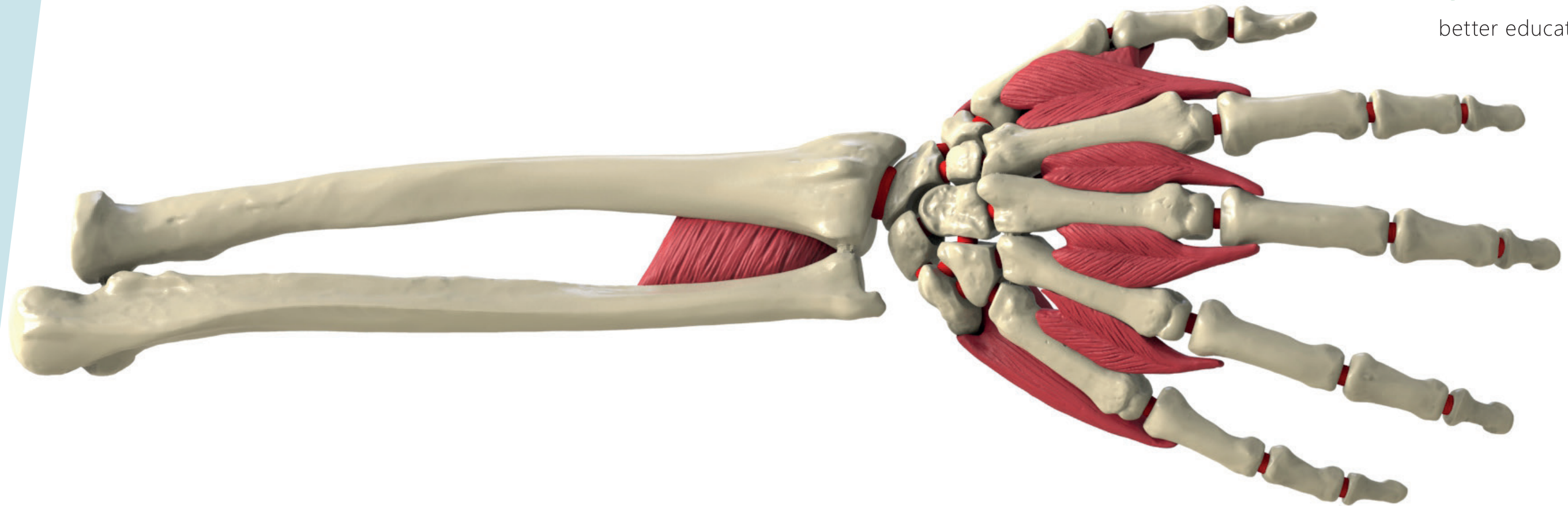


- Ⓐ M. dorsal interosseus I
- Ⓑ M. dorsal interosseus II
- Ⓒ M. dorsal interosseus III
- Ⓓ M. dorsal interosseus IV
- Ⓔ M. hypothenar group
- Ⓕ M. adductor pollicis
- Ⓖ M. thenar group
- Ⓗ M. pronator quadratus



Single Bone Hand

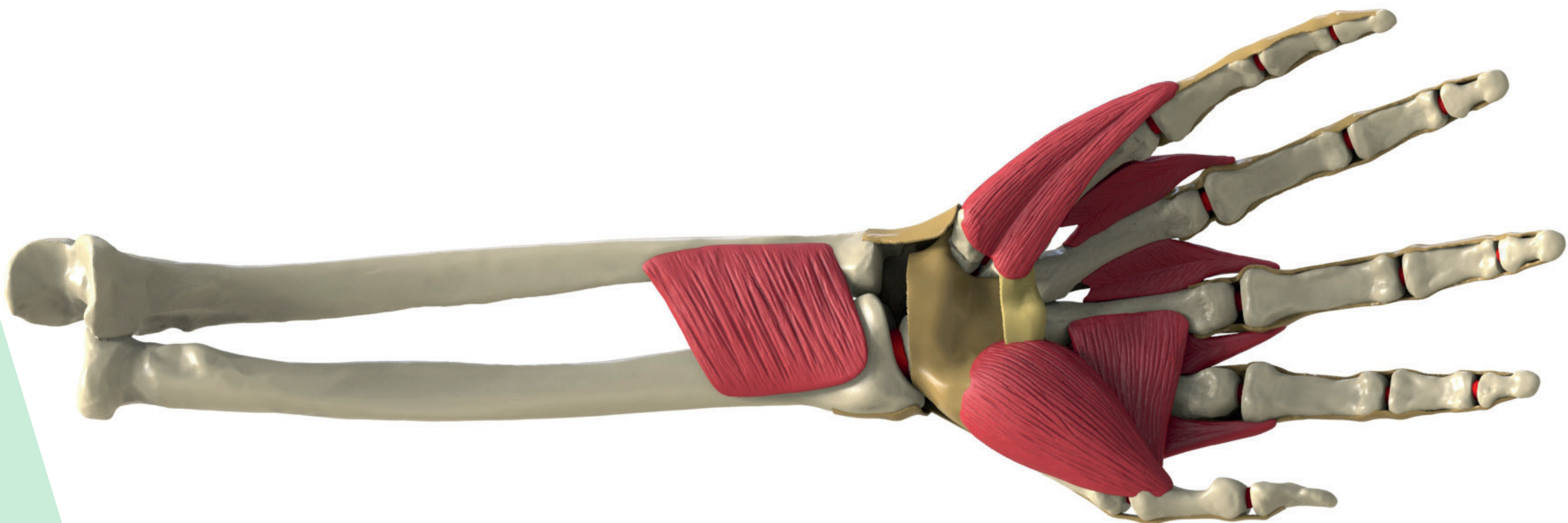
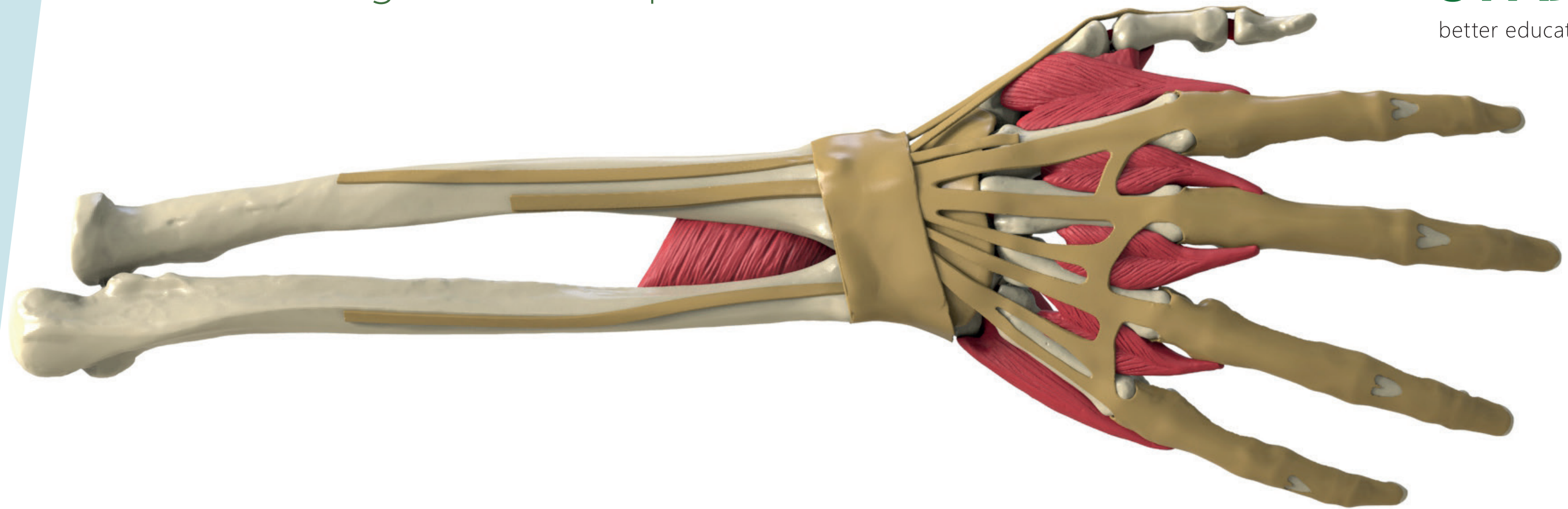


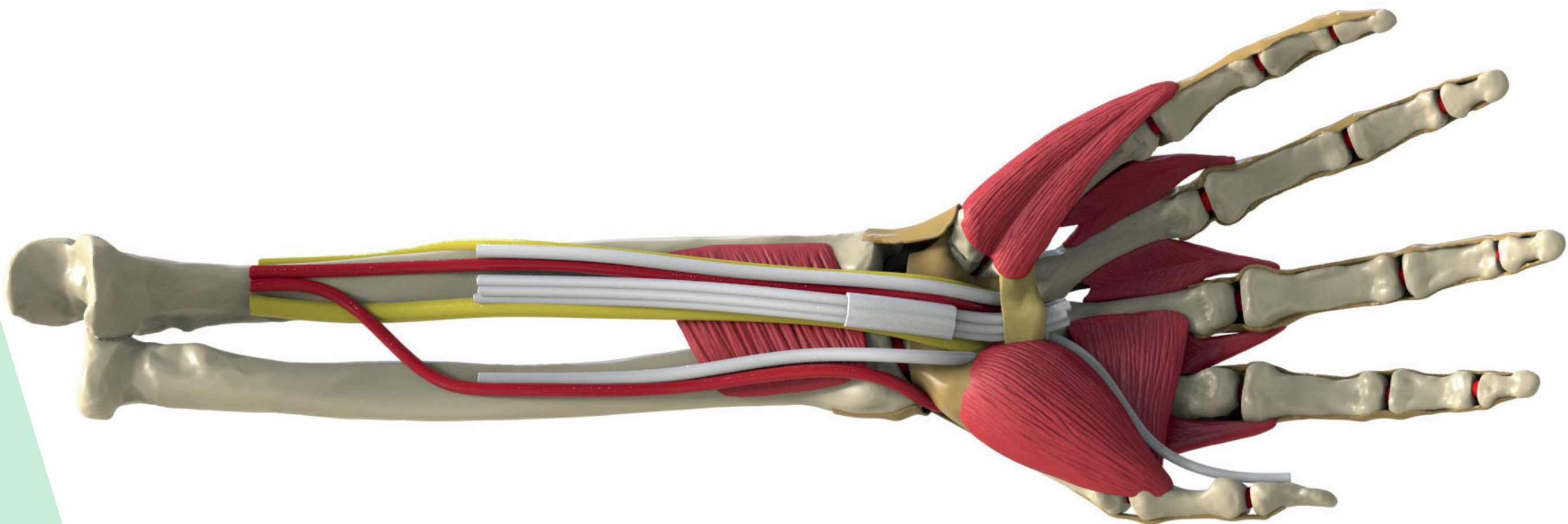
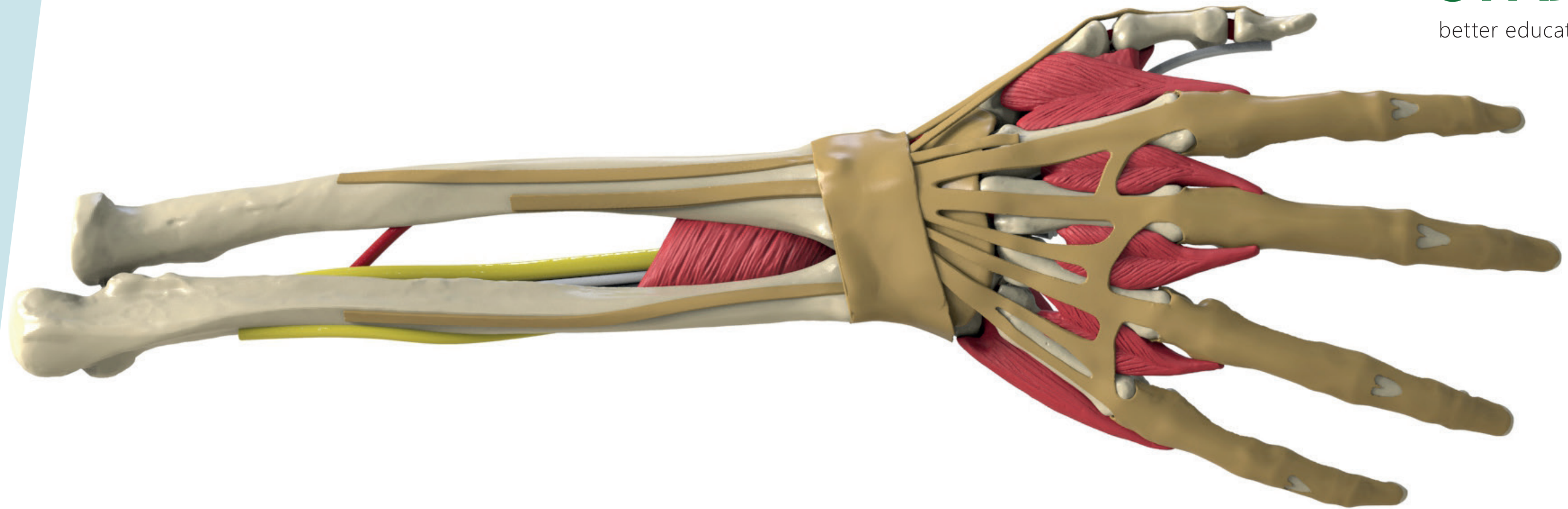


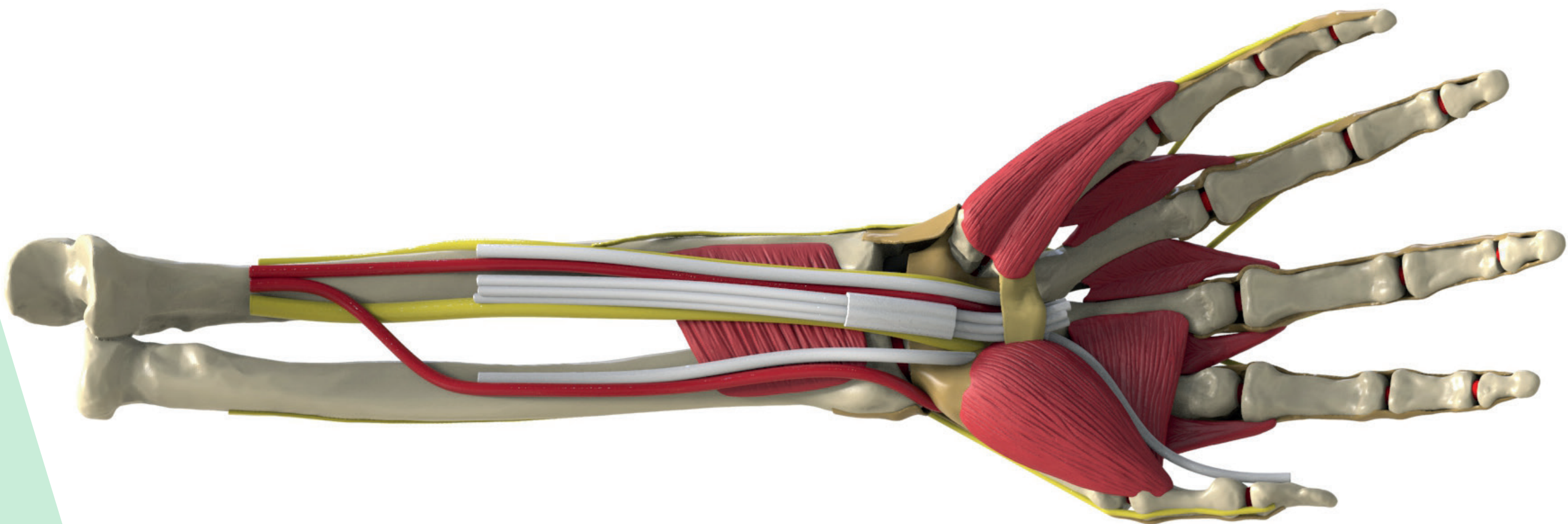
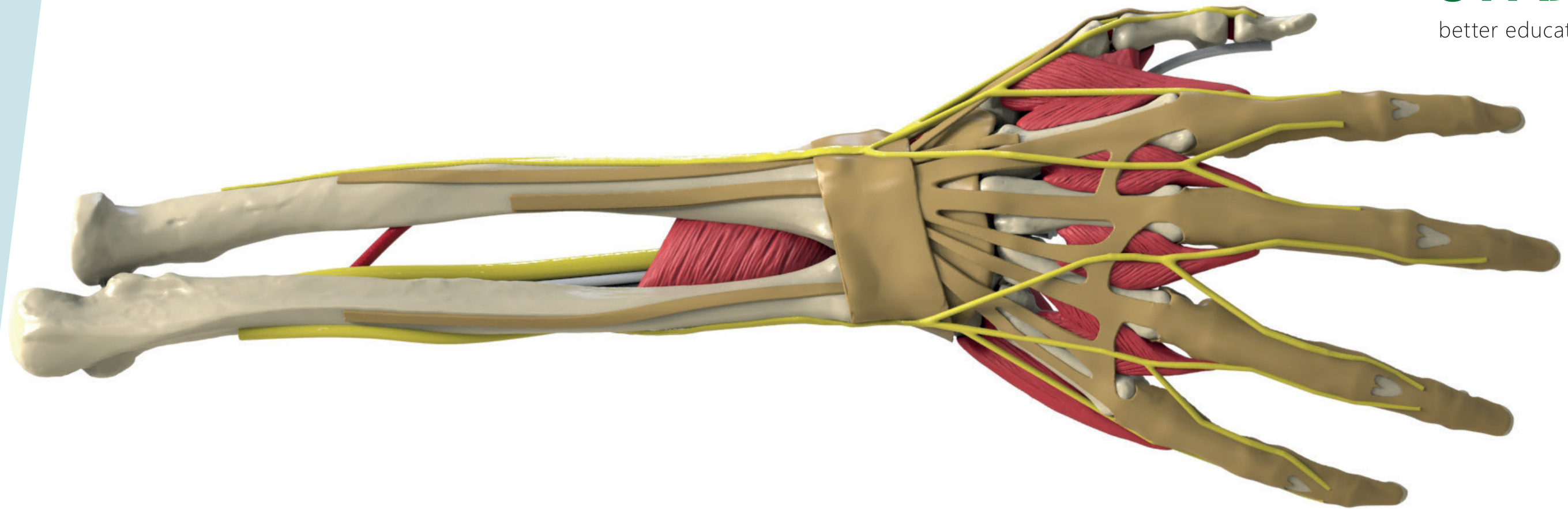
Tendons, Ligaments, Capsule

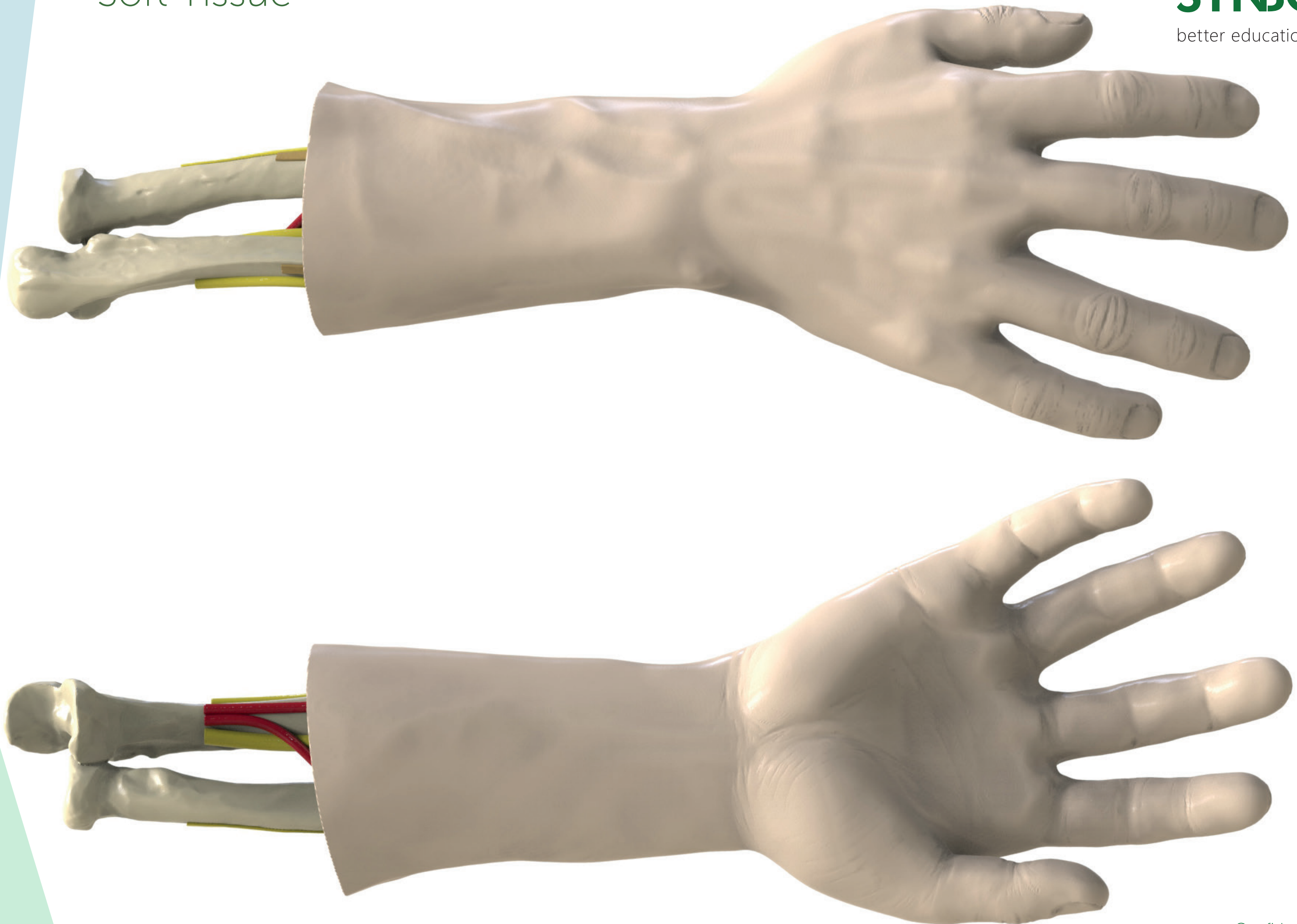
SYNBONE®

better education outcome









Transparent (schematic)

SYNBONE®

better education outcome

